

# McKissock's Reduction Mammoplasty Revisited: A Case Series Study with 12-months Follow-up

Mohamed F. Abozeid, MD,  
MRCS\*  
Hossam Tahseen, MD\*  
Inji Kenawi, MSc†

**Background:** Reduction mammoplasty is 1 of the highly challenging yet demanded plastic surgeries worldwide. Different techniques have been described, and their modifications are always evolving to achieve better aesthetic results. The objective of the current study was to explore the efficiency and safety of bipediced McKissock's technique with 3 newly added modifications as a reliable procedure for reduction mammoplasty.

**Methods:** The study was conducted in Royal Hospital, Cairo, Egypt, during the period from January 2015 to October 2016. It included 25 female patients undergoing reduction mammoplasty. All patients were evaluated by detailed history, careful physical examination, and photographed pre- and postoperatively. The new modifications included surgical undermining and thinning of the bipedicle for volume reduction and contour enhancement. The second modification was a dermal suspension of the lower pole for parenchymal support and longer breast shape stability. The third change was an S-shaped folding of the upper pole of the pedicle during nipple-areolar complex (NAC) transposition. After the operation, all subjects were followed up for 12 months to assess the outcomes of the procedure.

**Results:** Twenty-five female patients were included in the analysis of this study. The age of the patients ranged from 22 to 49 years with a mean age of 36.2 (7.3) years. The mean body mass index was  $30.5 \pm 4.3 \text{ kg/m}^2$  with a minimum of 24 and a maximum of 38. The average time of operation was 4 hours. The resected tissue was 630–980 g. The optimal aesthetic appearance of the breasts was achieved at 6–9 months postoperatively and maintained to 12 months. The maintenance of improvement was measured by the distance between the mid-clavicular point and 12 O'clock point of the NAC (12°NAC). It varied between 28 and 43 cm preoperatively (mean  $\pm$  SD,  $34.12 \pm 4.19 \text{ cm}$ ), and between 19 and 22 cm postoperatively (mean  $\pm$  SD,  $20.70 \pm 1.03 \text{ cm}$ ;  $P < 0.001$ ). The average percentage reduction in mid-clavicular point-NAC distance was  $38.7\% \pm 6.2\%$  with a minimum reduction of 27.6% and a maximum 48.8%. Moreover, the nipple to inframammary crease distance varied between 16 and 20 cm preoperatively (mean  $\pm$  SD,  $16.08 \pm 1.66 \text{ cm}$ ), and between 8 and 10 cm postoperatively (mean  $\pm$  SD,  $8.04 \pm 0.79 \text{ cm}$ ;  $P < 0.001$ ). The patients were very satisfied in most of the cases (20 cases), satisfied in 3 cases, and 2 cases were unsatisfied as they wanted slightly smaller breasts. No complications detected in 18 cases (72%), superficial wound dehiscence at the T-junction in 3 (12%), and seroma in 1 (4%). Two cases (8%) demanded smaller breasts and 1 case (4%) needed a surgical revision of widened scars after 11 months. The major drawbacks were NAC sensitivity alteration and the inability to lactate.

**Conclusion:** We can conclude that our modifications for the McKissock's technique with its maintained aesthetic shape in those patients are a reliable option that can be considered, as it is a simple, efficient, and satisfactory method that can improve the results of reduction mammoplasty operations. (*Plast Reconstr Surg Glob Open* 2018;6:e1791; doi: 10.1097/GOX.0000000000001791; Published online 11 June 2018.)

From the \*Department of Plastic Surgery, Faculty of Medicine, Cairo University, Egypt; and †Department of Plastic Surgery, Faculty of Medicine, Cairo University, Egypt.

Received for publication August 7, 2017; accepted April 3, 2018.

Copyright © 2018 The Authors. Published by Wolters Kluwer Health, Inc. on behalf of The American Society of Plastic Surgeons. This is an open-access article distributed under the terms of the Creative Commons Attribution-Non Commercial-No Derivatives License 4.0 (CCBY-NC-ND), where it is permissible to download and share the work provided it is properly cited. The work cannot be changed in any way or used commercially without permission from the journal.

DOI: 10.1097/GOX.0000000000001791

## INTRODUCTION

Reduction mammoplasty is 1 of the commonly demanded and performed operations in plastic surgery and has a high impact on the female patient's life.

**Disclosure:** The authors have no financial interest to declare in relation to the content of this article. The Article Processing Charge was paid for by the authors.

Supplemental digital content is available for this article. Clickable URL citations appear in the text.

There are many different approaches and techniques for reduction mammoplasty, each representing advantages and drawbacks. The challenging points are the ability to resect breast tissue adequately, symmetrically with preservation of NAC viability, sensibility, and function, while achieving a good sustained aesthetic result. Thus, it is continually evolving with new methods and modifications of these techniques.

Different pedicle techniques have been designed and named according to the site as superior,<sup>1</sup> inferior,<sup>2</sup> medial,<sup>3</sup> lateral,<sup>4</sup> central, or combinations of them.<sup>5</sup> The decision which of them is suitable based upon the degree of macromastia, breast ptosis and preference or expertise of the surgeon.

McKissock's<sup>6</sup> technique represents a well-vascularized dermo-glandular bipedicle for safe nipple-areola transposition in huge breast reduction, but it has been criticized as resulting in a flat breast with inadequate projection after long-term follow-up.<sup>7,8</sup>

Multiple modifications to the technique were done to prevent the major drawbacks of such a technique by beveling of the bipedicle and an S-shaped folding of the upper pole of the pedicle during nipple-areolar complex (NAC) transposition. Lastly, dermal suspension to the lower pole of the pedicle was added for prevention of the secondary ptosis of the reduced breasts on the long term.<sup>9</sup>

Thus, the rationale intended for the current study was to explore the efficiency and safety of bipedicted McKissock's technique with 3 new added modifications as a reliable procedure for reduction mammoplasty.

## PATIENTS AND METHODS

This study was conducted at the Royal Hospital, Cairo, Egypt, during the period from January 2015 to October 2016 with 12-month follow-up period. The goal of this study was explained in the Arabic language to all subjects before their enrollment in the study, and an informed consent form was signed by and obtained from all of them.

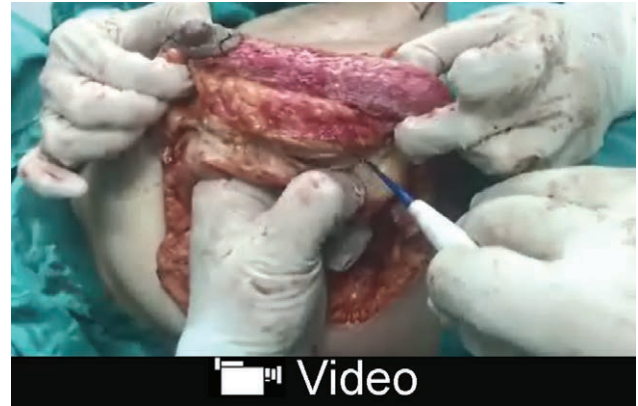We included 25 female patients, between 18 and 50 years, who were willing to undergo reduction mammoplasty. Exclusion criteria were American Society of Anesthesia score 3 or 4 (high risk for anesthesia), patients with organ failure, diabetes mellitus, collagen vascular diseases, and patients with bleeding tendencies.

### Preoperative and Postoperative Patient Assessment

All patients were evaluated by detailed history, careful physical examination, and photographed pre- and postoperatively using Nikon d3200 DSLR Camera, 18–55 mm lens. Photography views were standard anteroposterior, midlateral, and lateral views. Smoking was stopped at least 3 weeks before the procedure.

History included age of the patient, history of cardiac problems, liver disease, renal disease, or a recent drug intake and family history of breast disease. A detailed examination was done to assess for the current breast size, the degree of ptosis, and the status of the breast parenchyma.

We explained to the patients about the incisions, the scars, and discussed the idea of the operation, to know their expectations.



**Video Graphic 1.** See video, Supplemental Digital Content 1, which displays the new modification for McKissock's technique. This video is available in "Related Videos" section of the PRSGlobalOpen.com or at <http://links.lww.com/PRSGO/A778>.

Patients were assessed preoperatively, in the immediate postoperative period and at 3, 6, 9, and 12-month postoperative follow-up. Photographs were taken at each visit.

### Laboratory Investigations

Blood samples were taken from patients as a routine preoperative preparation for complete blood picture, coagulation profile, liver and kidney functions, and random blood sugar.

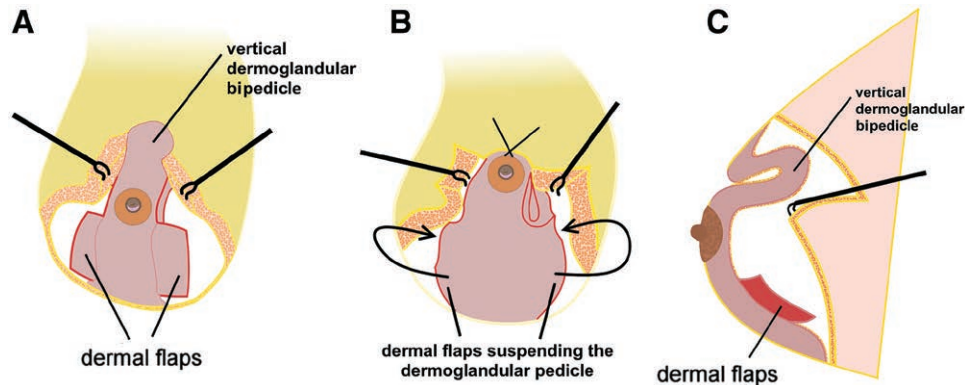
### Description of the New Modifications for the McKissock's Technique

Three modifications were added to the bipedicted McKissock's technique (modified vertical bipedicle technique). First, it included surgical undermining and thinning of the bipedicle for volume reduction and contour enhancement, which allows easier setting of the new NAC. The bipedicle was thinned up to 1.5 cm of thickness, basically between 1.5 and 2 cm (**see video, Supplemental Digital Content 1**, which displays the new modification for McKissock's technique. This video is available in "Related Videos" section of the PRSGlobalOpen.com or at <http://links.lww.com/PRSGO/A778>). The flap is 1.5–2 cm for the safety of blood supply because less than 1.5 cm can compromise the subdermal plexus, and if more than 2 cm represents overload on subdermal plexus by unnecessary fat layers and increases the overall volume of the residual tissues. Bipedicle flap length is maximum 4 times flap width to secure the ratio of 2:1 of both superior and inferior flaps.

The second modification was a dermal suspension of the lower pole for parenchymal support and longer breast shape stability. The third change was an S-shaped folding of the upper pole of the pedicle during NAC transposition to prevent their sagging and inversion.

### Preoperative Markings

Preoperative markings of all the patients were done in a standing position. First, a single midline vertical line was drawn from the suprasternal notch to the xiphoid



**Fig. 1.** Schematic illustration of the modified McKissock's technique. A, Surgical undermining and thinning of the bipedicle for volume reduction and contour enhancement. B, Dermal suspension of the lower pole for parenchymal support and longer breast shape stability. C, S-shaped folding of the upper pole of the pedicle during NAC transposition.

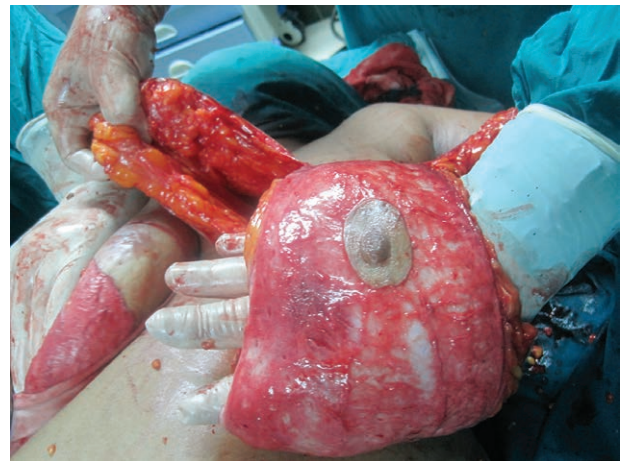process. Then, breast meridian line was drawn on each side, from the clavicle, 6.5–7.5 cm from the suprasternal notch, down to the NAC at 12 o'clock, and crossing the inframammary crease 10–12 cm from the midline, depending on the size of the rib cage or thorax. After that, the new NAC position was marked between 19 and 21 cm, and a classic Wise pattern<sup>10</sup> is drawn with vertical lines of 6–8 cm. Then, the inframammary fold was drawn in the upright; then, in the supine position, slightly above the actual one. Finally, the bipedicle was easily marked before the operation (Fig. 1).

### Operative Technique

Operations in all patients were done consecutively by the same surgeon under general endotracheal anesthesia, with the patients lying supine with abducted arms at 90 degrees. The surgical field is then sterilized and thoroughly draped. Prophylactic third-generation Cephalosporin antibiotic was given in a dose of 1 g IV before the incision and the infiltration of both breasts by lidocaine 2%, epinephrine 1:200 and normal saline solution 0.9%.

Using an areolotome, the size of the new areola and nipple was marked by an indentation of a 4.2 cm diameter. Besides, intradermal injection of the dermoglandular pedicle, and the intended dermal flaps were done for hydro-dissection and facilitation of the deepithelialization process. After that, incisions and dissection of the previously marked, Wise<sup>10</sup> pattern was performed, reaching the breast septum, with preservation of the superior and inferior pedicles (Figs. 2, 3).

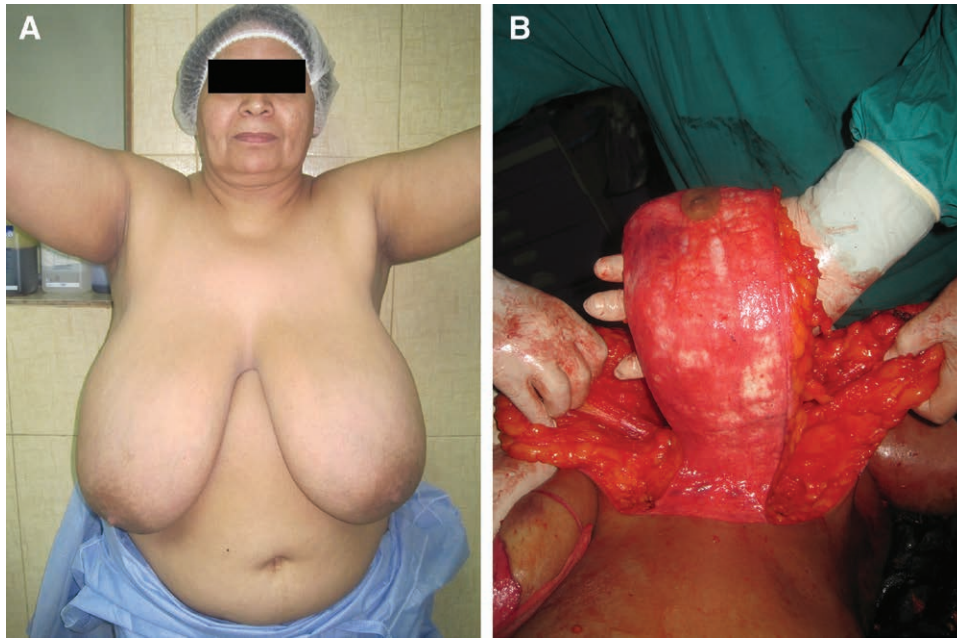
As a modification to the original McKissock technique, we performed surgical undermining and beveling of the central part of the breast to reduce bulkiness and make it easier for breast tissue molding. A minimum of 1.5 cm thickness of the dermoglandular flap remained in the subareolar part. For the adjustment of projection and NAC transposition, the upper pole of the bipedicle was folded in an S-shaped form and then sutured at 12 o'clock. The measurement of the upper pole ranged 14–16 cm to nipple and the inferior pole also 14–16 cm to nipple. The same procedure was done on both breasts.



**Fig. 2.** Intraoperative photograph showing the beveled bipedicle.

After finishing the resection, leaving lateral dermal flaps of 2 cm width and the NAC transposition, the patient's torso is elevated and positioned at 45 degrees. As a second modification of the technique, the lateral dermal flaps on either side of the dermoglandular pedicle were transposed and suspended in an internal brassiere form to the pectoral fascia without tension using 2-0 nonabsorbable polypropylene monofilament sutures. The base width of the bipedicle was kept between 8 and 10 cm. The aisles of dermal flaps were the same dimensions in all cases.

The lateral pillars were closed in subdermal and subcuticular layers to form the vertical limb of the inverted T wound. Suction drains were inserted bilaterally; then, the medial and lateral aspects of the inframammary incision were closed and sutured in layers, reaching the T-junction using simple inverted 2-0 and 3-0 absorbable subdermal sutures, and skin was closed with 3-0 subcuticular nonabsorbable polypropylene monofilament sutures. Adhesive sterile pads were used to cover the wounds, and the patient wore a special elastic supporting brassiere for 6 weeks.



**Fig. 3.** A case of gigantomastia and the intraoperative photograph of the bipedicle. A, Preoperative front view. B, Intraoperative view.

**Outcome Measures**

The primary outcome measure was to assess the aesthetic result of the modified McKissock’s technique (the bipedicted McKissock’s technique with 3 newly added modifications).

The assessment was done by the objective measurement of the distance between the mid-clavicular point (MCP) and 12 o’clock point of the NAC (12’NAC), in cm, pre- and postoperative at 9 months.

The secondary outcome measures were the measurement of the nipple to inframammary crease (IMC) before the operation and after the follow-up to assess the stability of the results over time, also, to quantify the short-term and long-term complications, as well as, to assess patients’ satisfaction with the results. Patients’ satisfaction was to be measured by using a satisfaction scale, where, 3 is very satisfied (the results matched all the patient’s desires), 2 is satisfied (not all the expectations were met, but still satisfied and do not request reoperation or secondary procedure), and one is unsatisfied.

**Statistical Analysis**

All statistical tests were done using a significance level of 95%. A value of  $P < 0.05$  was considered statistically significant. SPSS software (Statistical Package for the Social Sciences, version 20.0, SSPS Inc, Chicago, Ill.) was used for the statistical analyses. Data were presented as (mean  $\pm$  SD) or median (range) for continuous variables and as a frequency and percentage for categorical variables. Comparisons were made using the paired *t* test for continuous variables.

**RESULTS**

**Baseline Characteristics**

All 25 patients have had excessively large breasts with different degrees of ptosis. The age of the cases ranged

between 22 and 49 years (mean age,  $36.2 \pm 7.3$ ). The mean body mass index was  $30.5 \pm 4.3 \text{ kg/m}^2$  with a minimum of 24 and a maximum of 38.

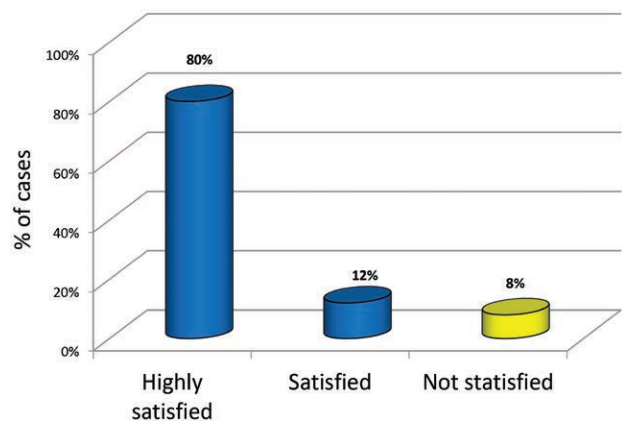
The average time of operation was 4 hours. The resected tissue was 630–980 g.

**The Postoperative Assessment: Patients’ Satisfaction**

Patients were asked about their overall satisfaction, particularly, satisfaction with shape, scar length, and nipple sensation after the operation. The patients were very satisfied in most of the cases (20 cases), satisfied in 3 cases, and 2 cases were unsatisfied as they wanted slightly smaller breasts, as shown in Figure 4.

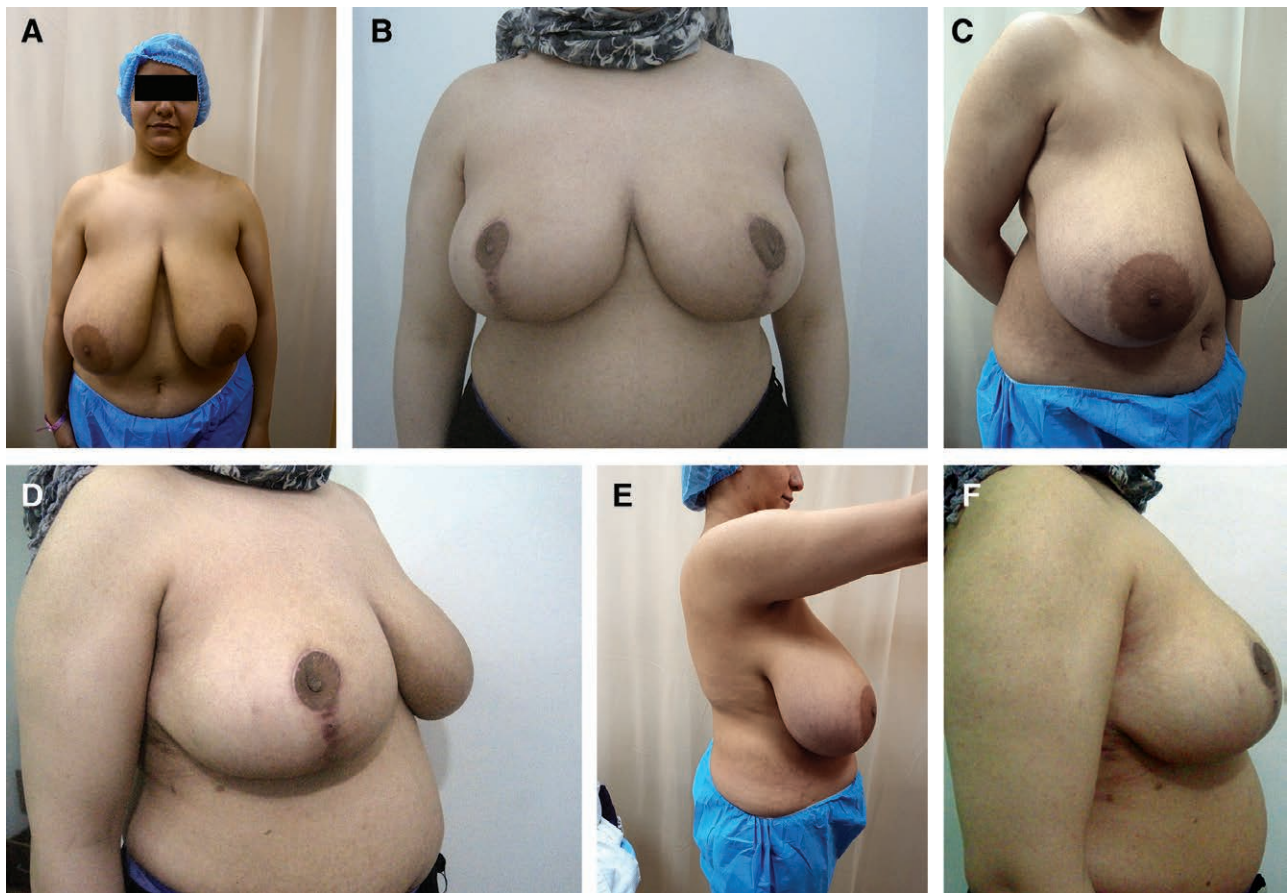**The Postoperative Assessment**

The optimal aesthetic appearance of the breasts was achieved at 6–9 months postoperatively. The better NAC



**Fig. 4.** Patients postoperative overall satisfaction.

Downloaded from http://journals.lww.com/prsgo by 11DITgeTcNGALIZ+AlUOpJVGoU1PKkIBFDpSTqIqIHGxX7G  
 XYo/qc+jaQSPGSlJErhxhBBZM8durfya3OIMMS4RzqzQGVESXDKOFxsp8MjMhSwMSZBlcJh6xhfbEzs66SGCvdy= on 09/12/22  
 022



**Fig. 5.** A case of 26-year-old female with preoperative gigantomastia and severe ptosis and postoperative results after 12 months. A, Front view preoperative. B, Front view 12-month postoperative. C, Angular view preoperative. D, Angular view 12-month postoperative. E, Lateral view preoperative. F, Lateral view 12-month postoperative.

projection was still maintained after 12-month follow-up in the form of better less hyperemic scars and softer breast glandular tissue with enhanced contour caused by natural draping with gravity (Figs. 5 & 6).

The maintenance of improvement was measured by the distance between the MCP and 12 o'clock point of the NAC (12'NAC) (Table 3). It varied between 28 and 43 cm preoperatively (mean  $\pm$  SD,  $34.12 \pm 4.19$  cm), and between 19 and 22 cm postoperatively (mean  $\pm$  SD,  $20.70 \pm 1.03$  cm;  $P$  value  $< 0.001$ ; Table 1). The average percentage reduction in MCP-NAC distance was  $38.7\% \pm 6.2\%$  with a minimum reduction of 27.6% and a maximum 48.8%.

Moreover, the nipple to IMC distance varied between 16 and 20 cm preoperatively (mean  $\pm$  SD,  $16.08 \pm 1.66$  cm), and between 8 and 10 cm postoperatively (mean  $\pm$  SD,  $8.04 \pm 0.79$  cm;  $P$  value  $< 0.001$ ; Table 1).

#### Postoperative Complications

No complications detected in 18 cases (72%), superficial wound dehiscence at the T-junction in 3 (12%), which were treated by repeated dressing with topical ointments and creams and seroma in 1 (4%), which completely resolved without further complications, as shown in Table 2. Two cases (8%) demanded smaller breasts, and 1 case (4%) needed surgical revision for widened scars after 11

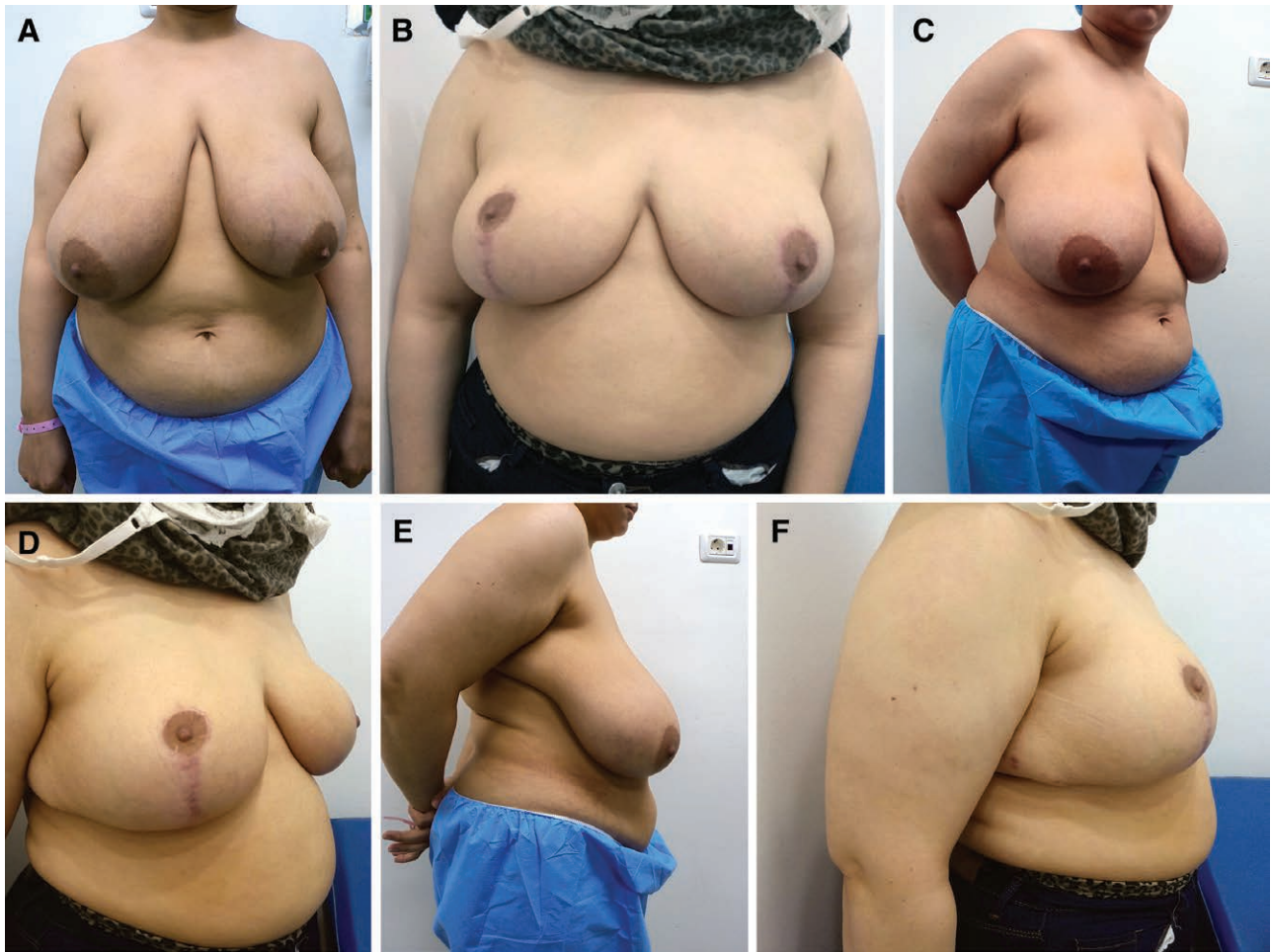
months. The major drawbacks were NAC sensitivity alteration and the inability to lactate.

Patients consented for the inability to lactate and the sensory changes they might experience postoperatively, and their main concern was basically on the appearance. No further sensory tests were done.

#### DISCUSSION

The most important goal of reduction mammoplasty is achieving a stable shape with a good projection of the breasts while minimizing the complications and ensuring a good blood supply to the nipple-areola complex.

Many reduction mammoplasty techniques have been described before, as the single pedicle techniques, the superior pedicle by Weiner,<sup>1</sup> the inferior pedicle described by Robbins,<sup>2</sup> the medial pedicle by Nahabedian et al.<sup>3</sup> and central by Gasperoni et al.<sup>11</sup> and are more commonly used nowadays. These techniques can produce good immediate postoperative results; however, they cannot be kept for a long time.<sup>12-14</sup> The lateral pedicle described by Skoog<sup>4</sup> is less likely used due to the bulky lateral fullness it produces. The horizontal bipedicle technique has been described by Strombeck<sup>5</sup> but was also avoided, due to the same aesthetic reasons. The vertical bipedicle described by McKissock<sup>6</sup> has the advantages of increased vascular safety to prevent



**Fig. 6.** A case of 46-year-old female with preoperative gigantomastia and severe ptosis and postoperative results after 12 months. A, Front view preoperative. B, Front view 12-month postoperative. C, Angular view preoperative. D, Angular view 12-month postoperative. E, Lateral view preoperative. F, Lateral view 12-month postoperative.

the complication of nipple-areola complex necrosis, while at the same time achieving a fine aesthetic breast shape.

After the first description of the superior pedicle mammoplasty Arie (1957), the technique had been subjected to some refinements by Ivo Pitanguy in 1967.<sup>15,16</sup> In 1973, Weiner brought it to the United States describing it for reductions and mastopexy.<sup>17</sup> Furthermore, Orlando and Guthrie<sup>18</sup> demonstrated the superomedial pedicle technique, which varied only in the more medially directed superior pedicle.<sup>19</sup> Moreover, Arufe et al.<sup>20</sup> confirmed

adequate vascularity of the superior pedicle with preoperative arteriograms on several patients. Durability of results of breast reduction with the superomedial intraparenchymal pillar suturing techniques was demonstrated by Elizabeth Hall-Findlay, which showed good long-term shape that decreased the incidence of bottoming out of the breast over time.<sup>21</sup>

The primary concern in our research is to add longevity to the new breast shape with an ultra-safe and yet easy technique. The results of the current study showed that the new modifications added to the McKissock's technique are successful in most of the subjects, with highly satisfactory outcomes. Besides, the assessment of the

**Table 1. MCP to 12'NAC Distance and Nipple to IMC Distance in cm**

Statistic	MCP-NAC		Nipple-IMC	
	Preoperative	12-mo Postoperative	Preoperative	12-mo Postoperative
Mean	34.12	20.70	16.08	8.04
SD	4.19	1.03	1.66	0.79
Median	33	21	16	8
Minimum	28	19	14	7
Maximum	43	22	20	10
<i>P</i>	< 0.001		< 0.001	

**Table 2. Postoperative Complications**

Outcome	No. Patients	%
All sample	25	100
No complication	18	72
Superficial wound dehiscence	3	12
Demanded smaller breasts	2	8
Needed secondary surgery	1	4
Seroma	1	4

**Table 3. Cases Measurements**

Patient Number	MCP-NAC		Nipple to IMC	
	Preoperative	Postoperative	Preoperative	Postoperative
1	29	21	15	8
2	31	21	16	8
3	28	19.5	14	7
4	32	21	16	8
5	39	20	17	9
6	37	20	17	8
7	40	21	18	9
8	33	20	17	7
9	37	22	18	9
10	36	21	17	8
11	30	21	15	8
12	29	19.5	14	7
13	31	20	15	7
14	34	22	16	8
15	38	21	17	8
16	32	19	15	7
17	33	22	14	8
18	41	22	18	8
19	32	20	14	8
20	30	19	14	7
21	34	19.5	16	8
22	30	20	14	8
23	39	22	18	9
24	35	22	17	9
25	43	22	20	10

maintenance of improvement of ptosis was reported by the objective measurements of the distance between MCP and NAC in cm and the nipple to IMC distance. All postoperative complications were resolved completely during the follow-up period.

McKissock's technique has some disadvantages resulting in broad breasts, long submammary scars, and secondary ptosis or pseudoptosis, caused by the bulky bipedicle. Our modifications include a shorter folded superior pedicle, and a narrow suspended inferior pedicle, which result in shorter submammary incisions. Thinning of the bipedicle increases its malleability in forming a projecting breast shape, while the dermal suspension of McKissock's vertical bipedicle flap technique is an easy modification that prevents its drawbacks of secondary ptosis.

Hinderer<sup>9</sup> described a dermal suspension technique in reduction mammoplasty for suspending the gland in different breast sizes and also in mastopexy. There are additional advantages of dermal suspension of the bipedicle, including the prevention of flat breasts appearance, while also decreasing the tension on the medial and lateral pillars of skin flaps, and thus enhancing the process of healing and minimizing scar formation. Menderes et al.,<sup>12</sup> compared the McKissock's technique with and without dermal suspension and found that the outcome was better with dermal suspension, due to the prevention of bottoming out of the inferior pole and the longest sustained aesthetic shape.

In our study, postoperatively, there was no compromise of the venous return or any signs of nipple-areola complex congestion from the S maneuver.

A critical aspect in reduction mammoplasty is the patient satisfaction of the aesthetic results in the long term. The patients operated on by the modifications of McKissock's technique with dermal suspension, demonstrated

excellent results in breast shape, size, and symmetry. The most fulfilling part was the positive body image, which patients attained after the operation. All patients have a more active social and physical life and are no longer burdened with hypertrophic breasts and the associated signs and symptoms.

Further comparisons to the technique and its modifications are highly recommended for enhanced long-lasting aesthetic breast appearance after reduction mammoplasty.

## CONCLUSIONS

We can conclude that our modifications for the McKissock's technique with its maintained aesthetic shape in those patients are a reliable option that can be considered as it is a simple, efficient, and satisfactory method, which can improve the results of reduction mammoplasty operations.

Mohamed Fathi Abozeid

1190 Zahraa Nasr City

Cairo, Egypt

E-mail: dr.mohamed.f.abuzeid@gmail.com

## ACKNOWLEDGMENTS

We would like to acknowledge Dr. Emad R. H. Issak (ClinA-mygate) for his efforts in statistical analysis and editing of this manuscript.

## REFERENCES

- Weiner DL, Dolich BH, Mclat MI Jr. Reduction mammoplasty utilizing the superior pedicle technique: a six-year retrospective. *Aesthetic Plast Surg.* 1982;6:7-14.
- Robbins TH. A reduction mammoplasty with the areola-nipple based on an inferior dermal pedicle. *Plast Reconstr Surg.* 1977;59:64-67.
- Nahabedian MY, McGibbon BM, Manson PN. Medial pedicle reduction mammoplasty for severe mammary hypertrophy. *Plast Reconstr Surg.* 2000;105:896-904.
- Skoog T. A technique of breast reduction; transposition of the nipple on a cutaneous vascular pedicle. *Acta Chir Scand.* 1963;126:453-465.
- Strombeck JO. Mammoplasty: report of a new technique based on the two-pedicle procedure. *Br J Plast Surg.* 1960;13:79-90.
- McKissock PK. Reduction mammoplasty with a vertical dermal flap. *Plast Reconstr Surg.* 1972;49:245-252.
- Ramon Y, Sharony Z, Moscona RA, et al. Evaluation and comparison of aesthetic results and patient satisfaction with bilateral breast reduction using the inferior pedicle and McKissock's vertical bipedicle dermal flap techniques. *Plast Reconstr Surg.* 2000;106:289-295; discussion 295.
- Hirshowitz B, Moscona AR. Modification of the bipediced vertical dermal flap technique in reduction mammoplasty. *Ann Plast Surg.* 1982;8:363-369.
- Hinderer UT. Mammoplasty: the dermal brassière technique. *Aesthetic Plast Surg.* 1978;2:1-20.
- Wise RJ. A preliminary report on a method of planning the mammoplasty. *Plast Reconstr Surg.* 1956;17:367-375.
- Gasperoni C, Salgarello M, Gasperoni P. A personal technique: mammoplasty with J scar. *Ann Plast Surg.* 2002;48:124-130.
- Menderes A, Mola F, Vayvada H, et al. Dermal suspension flaps for McKissock's vertical bipedicle flap vs. classical McKissock's technique: comparison of aesthetic results and patient satisfaction. *Br J Plast Surg.* 2005;58:209-215.

13. Echo A, Guerra G, Yuksel E. The dermal suspension sling: shaping the inferior pedicle during breast reduction. *Aesthetic Plast Surg.* 2011;35:608–616. doi: 10.1007/s00266-010-9632-5. Epub 2010 Dec 7.
14. Abdelaal MM, Aboelatta YA. Dermo-fascial suspension for better contouring and long lasting results in reduction mammoplasty. *Aesthetic Plast Surg.* 2015;39:78–83.
15. Arie G. Una nueva tecnica de mastoplastia. *Rev Iber Latino Am Cir Plast.* 1957;3:28.
16. Pitanguy I. Surgical treatment of breast hypertrophy. *Br J Plast Surg.* 1967;20:78–85.
17. Weiner DL, Aiache AE, Silver L, et al. A single dermal pedicle for nipple transposition in subcutaneous mastectomy, reduction mammoplasty, or mastopexy. *Plast Reconstr Surg.* 1973;51:115–120.
18. Orlando JC, Guthrie RH Jr. The superomedial dermal pedicle for nipple transposition. *Br J Plast Surg.* 1975;28:42–45.
19. Hugo NE, McClellan RM. Reduction mammoplasty with a single superiorly-based pedicle. *Plast Reconstr Surg.* 1979;63:230–234.
20. Arufe HN, Erenfryd A, Saubidet M. Mammoplasty with a single, vertical, superiorly-based pedicle to support the nipple-areola. *Plast Reconstr Surg.* 1977;60:221–227.
21. Hall-Findlay EJ. A simplified vertical reduction mammoplasty: shortening the learning curve. *Plast Reconstr Surg.* 1999;104:748–759; discussion 760–3.